



Spontaneous Peeling of an Epiretinal Membrane in an Eye with Treated Proliferative Diabetic Retinopathy

Ananth Sastry MD, C. Ellis Wisely MD MBA, Sejal D. Patel*, Lucas McNeill BS, Sharon Fekrat MD FASRS

Duke Eye Center, Duke University School of Medicine, Durham, NC, USA

DOI: <https://doi.org/10.62856/djcro.v1i1.19>

*Corresponding author:

Sejal D. Patel

Duke Eye Center

Durham, NC 27710-3802, USA

E-mail: sejal.d.patel@duke.edu

Introduction

An epiretinal membrane (ERM) is formed by the proliferation of cells and extracellular matrix over the internal surface of the retina. It most commonly presents in adults aged 50 or older after the development of a posterior vitreous detachment (PVD).^{1,2,3} While the exact cause of ERM development is not found in the majority of eyes (idiopathic), there are secondary causes for the development of ERM including retinal vascular disease, trauma, intraocular inflammation, and incisional or laser surgery.⁴ Cellular contraction of an ERM can result in tangential tractional forces on the retina contributing to distortion of the contour of the retinal surface and in some eyes, cystoid macular edema (CME).⁵ This may result in metamorphopsia, monocular diplopia, or decreased visual acuity (VA). In such cases, surgical removal of a visually significant ERM may be recommended to increase the chances of improved retinal architecture, which can then lessen anatomical distortion and improve VA.⁶

On rare occasions, ERMs have been shown to spontaneously separate from the inner surface of the retina and release traction on the macula, which often results in improvement of visual symptoms. Scattered case reports demonstrate spontaneous release of an ERM from the macular surface after the development of a PVD.^{7, 8, 9} A larger retrospective study showed that this can also occur in eyes with pre-existing PVDs. Most reported cases of spontaneous resolution of ERMs have occurred in patients with idiopathic ERM.¹⁰

We report a case of a patient with attached posterior hyaloid and proliferative diabetic retinopathy treated with panretinal laser photocoagulation who developed a prominent secondary ERM. Over a 5-year period, there was liquefaction of the vitreous gel and separation of the posterior hyaloid along with progressive and spontaneous release of the ERM and concurrent relaxation and improvement in foveal contour. This case demonstrates that a secondary ERM can also spontaneously peel following PVD formation.

Case Report

A 63-year-old pseudophakic male with type 1 diabetes mellitus developed proliferative diabetic retinopathy that was treated with panretinal laser photocoagulation. On initial presentation, corrected VA was 20/50 in the right eye and 20/25 in the left eye. Slit-lamp examination was unremarkable. Dilated fundus examination of the left eye showed attached posterior hyaloid, proliferative diabetic retinopathy treated with panretinal laser photocoagulation, and an ERM. Spectral domain optical coherence tomography (SD-OCT) confirmed the presence of the ERM with distortion of the foveal contour, but without CME or PVD (Figure 1A). Observation was recommended.

One year later, the VA and examination were unchanged. SD-OCT demonstrated a partial PVD with residual attachment at the optic nerve along with horizontal contraction of the ERM and increased corrugation of the foveal contour (Figure 1B).

Over the ensuing 4 years, the corrected VA remained unchanged, but the OCT showed progressive contraction and coiling of the ERM, giving it a rolled-up appearance (Figure 1C, a-d). Five years after presentation, the ERM had retracted and curled up nasally, so it was no longer over the foveal center. The foveal contour improved (Figure 1C, d). Corrected visual acuity remained 20/25 in the left eye.

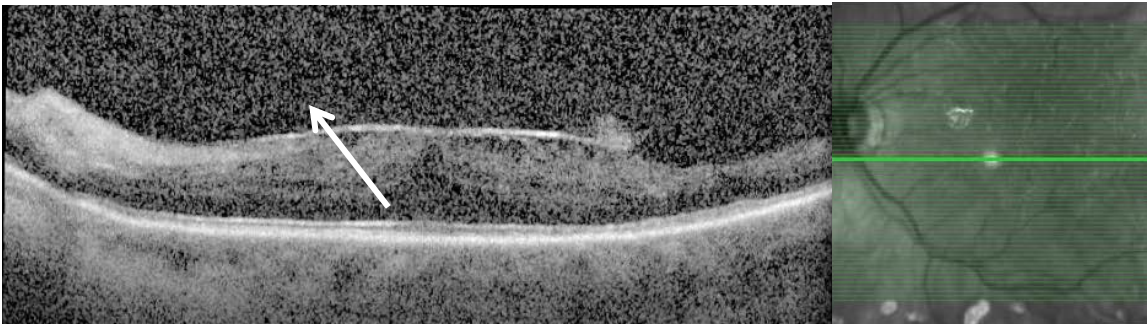


Figure 1A.

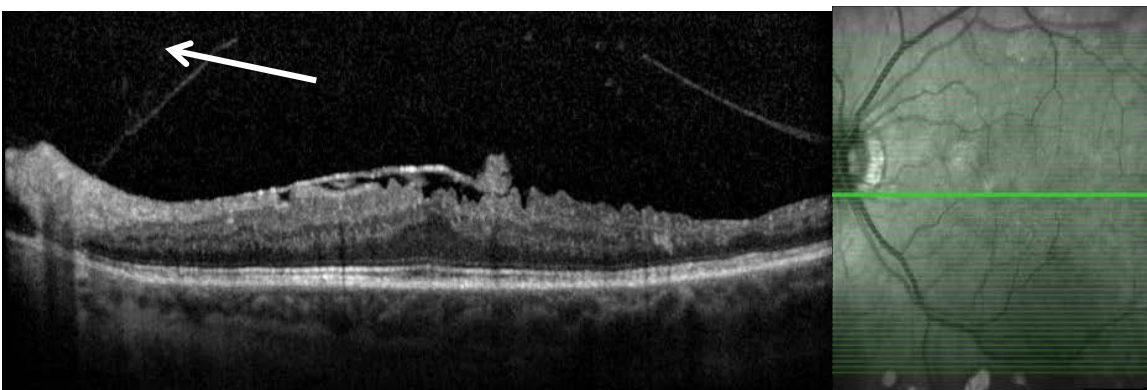


Figure 1B.

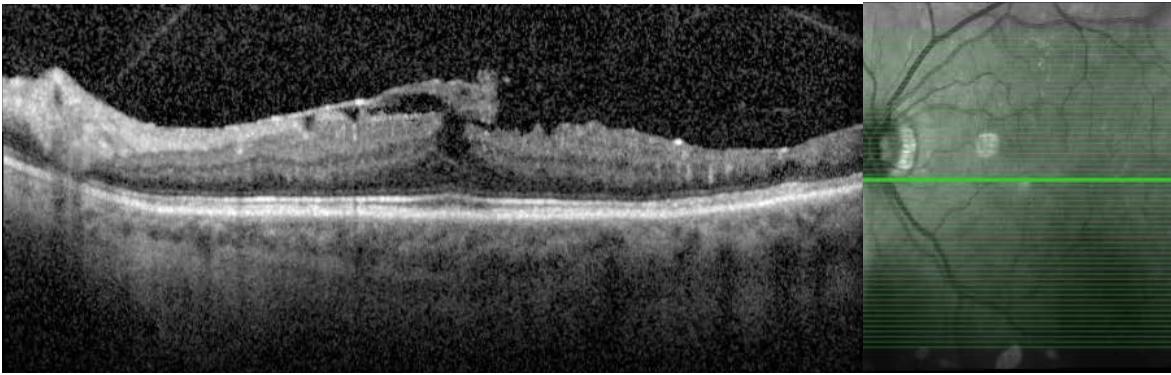


Figure 1C, A.

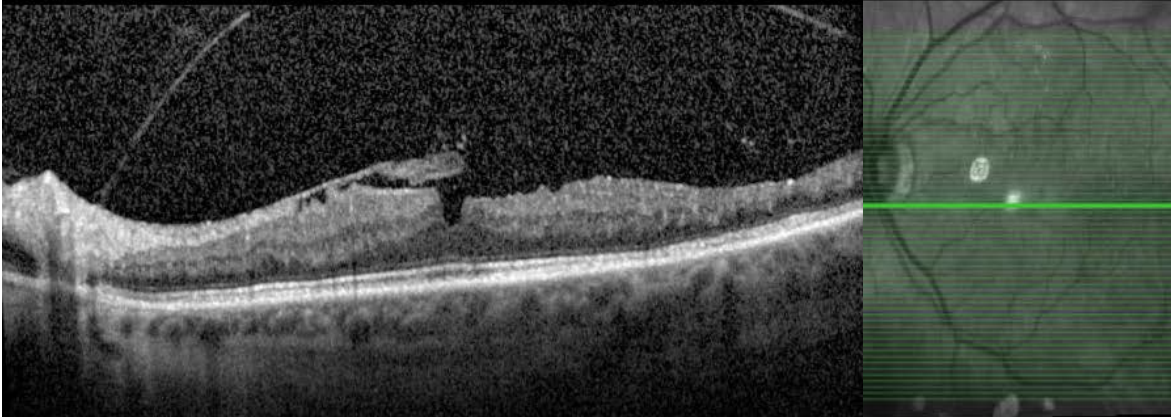


Figure 1C, B.

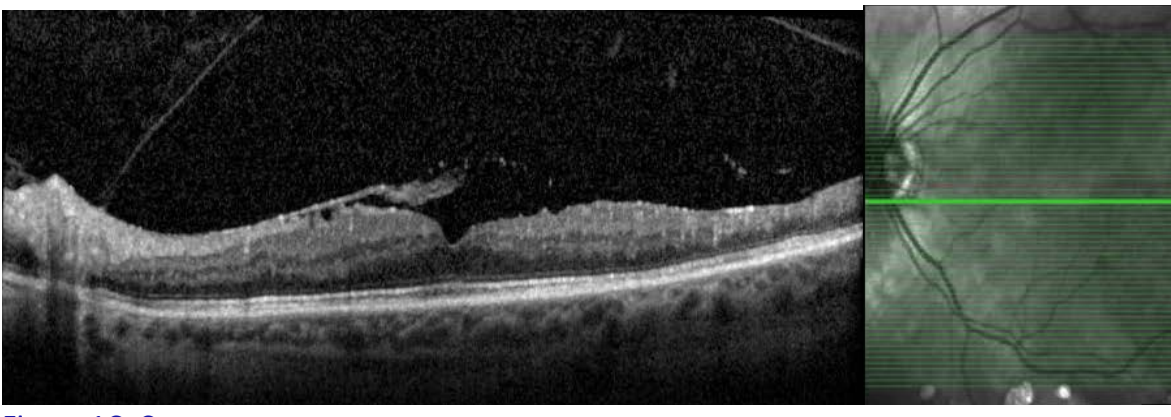


Figure 1C, C.

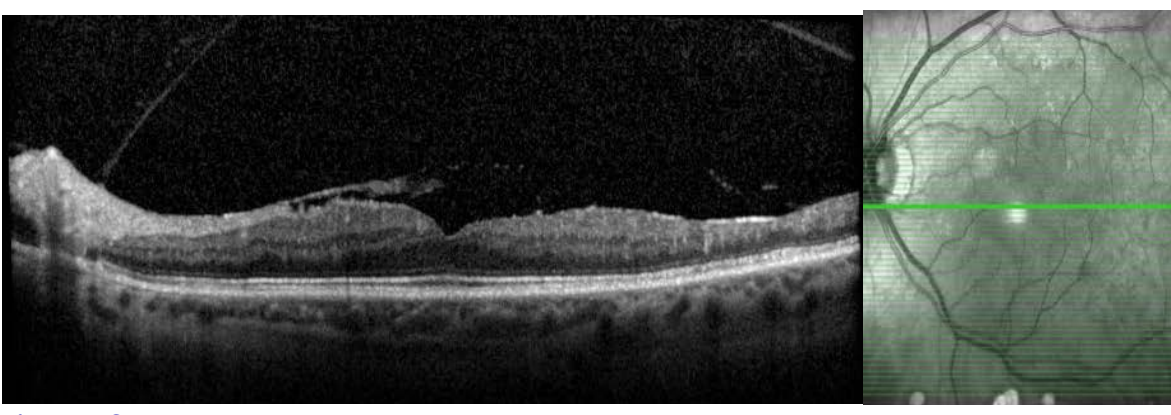


Figure 1C, D.

Figure 1. Spectral domain optical coherence tomography of the left eye at initial presentation (**1A**) and subsequent annual follow-up from years 1 through 5 (**1B-C**). The initial presentation shows an adherent posterior hyaloid and an epiretinal membrane (arrow) contributing to distortion of the foveal contour, but without cystoid macular edema or outer retinal abnormality (**1A**). At year 1, examination shows interval development of a vitreomacular separation (arrow) and increased corrugation and contraction of the epiretinal membrane (**1B**). Each subsequent follow-up shows the epiretinal membrane progressively releasing from the fovea with a rolled-up appearance and concurrent progressive relaxation of the retina with improvement of foveal contour (**1C**).

Discussion

Spontaneous release of an ERM is an uncommon but known entity that has been described in literature. The majority of published case reports described this occurrence in adults over 50 years old with idiopathic ERMs that self-peeled after the development of a PVD.^{7,9} Yang et al. reported the largest study using SD-OCT to retrospectively analyze 1,248 eyes with idiopathic ERMs and found spontaneous release in 1.5% of 1,091 eyes with pre-existing PVD and 13.4% of 157 eyes without pre-existing PVD. Two cases in their study demonstrated spontaneous separation without the development of a PVD.¹⁰ The spontaneous release of idiopathic ERM has also been described in younger patients. Meyer et al. presented 6 patients under the age of 30 with idiopathic ERM that spontaneously resolved. Only 1 of 5 eyes developed a PVD.¹¹

Idiopathic ERM has been shown to self-peel after laser photocoagulation. Sumers et al. describe a 19-year-old male with sickle cell retinopathy whose ERM self-peeled after panretinal laser photocoagulation, and a 65-year-old female with ERM after barrier laser retinopexy for a peripheral horseshoe tear. The PVD status in each of these cases was not specified.¹²

Two reported cases have described eyes with secondary ERMs that self-peeled. Ray et al. reported a 23-year-old male who developed an ERM and vitreous hemorrhage after Nd:YAG laser injury to the macula, with spontaneous improvement several months later.¹³ Mesner similarly demonstrated a case of an 8-month-old male who developed an ERM after ocular trauma that subsequently self-regressed.⁸ It is interesting to note that both of these cases occurred in young patients after an eye injury.

Our case reported herein has several features that make it unique compared to those previously described in the literature. Our case demonstrates spontaneous retraction of a secondary (non-idiopathic) ERM following formation of a PVD after panretinal laser photocoagulation to treat proliferative diabetic retinopathy in a patient over 50 years old. The pattern of ERM contraction and self-peeling as demonstrated on SD-OCT differs from the pattern described by Yang et al.¹⁰ The reported pattern of ERM release in an eye with concurrent PVD formation showed a peeling up of the ERM into the vitreous cavity, whereas in our patient, there was horizontal contraction nasally as the ERM self-peeled off the fovea following PVD formation. This is particularly interesting since one might expect the ERM to pull up into the vitreous cavity along with the posterior hyaloid since vitreomacular adhesion and traction particularly in an eye with proliferative diabetic retinopathy often follows a more vertical vector.¹⁴

Conclusion

We present a case of a secondary ERM in an eye with regressed proliferative diabetic retinopathy that contracted, remodeled over time, and spontaneously peeled off the foveal center following PVD formation. This case illustrates an ERM that involuted via tangential contraction and released traction on the foveal center in a diabetic eye.

References

1. Bringmann A, Wiedemann P. Involvement of Muller Glial Cells in Epiretinal Membrane Formation. *Graefes Arch Clin Exp Ophthalmol*. 2009;247:865-883.
2. Lesnik Obsertein SY et al. Evidence that Neurites in Human Epiretinal Membranes Express Melanopsin, Calretinin, Rod Opsin and Neurofilament Protein. *Br J Ophthalmol*. 2011;95:266-272.
3. Ozgonul C, Besirli C. Self-peeling Epiretinal Membrane. *Retinal Cases and Brief Reports*. 2018;12:196-199.
4. McLeod D, Hiscott PS, Grierson I. Age-related Cellular Proliferation at the Vitreoretinal Juncture. *Eye*. 1987.1: 263-281.
5. Jumper JM, Embabi SN, Toth CA, et al. Electron Immunocytochemical Analysis of Posterior Hyaloid Associated with Diabetic Macular Edema. *Retina*. 200;20:63-68.
6. Pesin SR, Olk RJ, Grand MG, et al. Vitrectomy for Premacular Fibroplasia. Prognostic Factors, Long-Term Follow-Up, and Time Course of Visual Improvement. *Ophthalmology*. 1991;98:1109-1114.
7. Allen AW, Gass JD. Contraction of a Perifoveal Epiretinal Membrane Simulating a Macular Hole. *Am J Ophthalmology*. 1976;92:684-691.
8. Mesner KH. Spontaneous Separation of Preretinal Macular Fibrosis. *Am J Ophthalmol*. 1977;83:9-11
9. Greven CM, Slusher MM, Weaver RG. Epiretinal Membrane Release and Posterior Vitreous Detachment. *Ophthalmology*. 1998;95:902-905.
10. Yang HS, Hong JW, Kim YJ, et al. Characteristics of Spontaneous Idiopathic Epiretinal Membrane Separation in Spectral Domain Coherence Tomography. *Retina*. 2014;34:2079-2087.
11. Meyer et al. Spontaneous Separation of Epiretinal Membrane in Young Subjects: Personal Observations and Review of the Literature. *Graefe's Arch Clin Exp Ophthalmol*. 2004;242:977-985.
12. Ray S, Topping T, Young L.H. Spontaneous Peeling of Epiretinal Membrane Associated with Nd:YAG Laser Injury. *Arch Ophthalmol*. 2001;119(1):137-9.
13. Summers KD, Jampol LM, Goldberg MF, et al. Spontaneous Separation of Epiretinal Membranes. *Arch Ophthalmol*. 1980;98:319-320.
14. Agarwal D, Gelman R, Prospero Ponce C, et al. The Vitreomacular Interface in Diabetic Retinopathy. *J Ophthalmol*. 2015;2015:392983.

Statement of Ethics

This case report adheres to patient confidentiality and ethical principles in accordance with the guidelines of the Declaration of Helsinki and relevant local regulations.

Conflict of Interest Statement

The authors declare no conflicts of interest related to this topic.

Funding

This work received no funding or grant support.

Authorship

We attest that all authors contributed significantly to the creation of this manuscript, each having fulfilled the criteria as established by the ICMJE.