



# Endogenous Endophthalmitis Caused by *Granulicatella adiacens*

**Janiece L. Rosado MA<sup>1,2</sup>, Melissa Yuan MD<sup>2</sup>, Dan A. Gong MD<sup>2\*</sup>**

<sup>1</sup>Jacobs School of Medicine and Biomedical Sciences, University at Buffalo, Buffalo, NY

<sup>2</sup>Department of Ophthalmology, Massachusetts Eye and Ear, Harvard Medical School, Boston, MA

DOI: 10.62856/djcro.v5.36

\*Corresponding Author

**Dan A. Gong MD**

Department of Ophthalmology

Massachusetts Eye and Ear, Harvard Medical School, Boston, MA

E-mail: [dan\\_gong@meei.harvard.edu](mailto:dan_gong@meei.harvard.edu)

## Introduction

Endophthalmitis is a severe intraocular infection and can be classified as exogenous or endogenous. Endogenous endophthalmitis, which is seen less commonly than exogenous endophthalmitis, occurs due to hematogenous spread from a systemic source of infection, often linked to recent hospitalization, indwelling catheters, or intravenous drug use (IVDU).<sup>1</sup> Causative agents of endogenous endophthalmitis encompass fungal and bacterial pathogens. Fungal organisms may include *Candida* and *Aspergillus*, while bacterial species include gram-positive bacteria such as *Streptococcus* and *Staphylococcus*.<sup>1</sup> However, *Granulicatella adiacens*, gram-positive cocci typically linked to infective endocarditis, has not been previously reported as a cause of endogenous endophthalmitis.<sup>2</sup> In this report, we present a case of endogenous endophthalmitis caused by *G. adiacens*, with a clinical appearance initially concerning for fungal endophthalmitis.

## Case Report

A 22-year-old male with known IVDU presented with subacute vision loss and redness in his left eye. These symptoms began 6 days after his last injection of heroin. He reported no previous surgeries, hospitalizations, uveitides, or autoimmune diseases. His IVDU history was notable for 9 years of intravenous use, predominantly opiates such as heroin and fentanyl.

During the initial examination, visual acuity was 20/20 in the right eye and hand motion in the left eye. Intraocular pressure was normal in both eyes. Slit lamp examination of the left eye showed conjunctival injection and dense anterior chamber cell, but no layered hypopyon. A dilated fundus examination demonstrated vitreous haze. B-scan ultrasonography revealed dense vitritis, consistent with a suspected endophthalmitis in the left eye. An endogenous source was suspected given the patient's known IVDU and no prior eye surgery or open globe injury, even though blood cultures were negative.

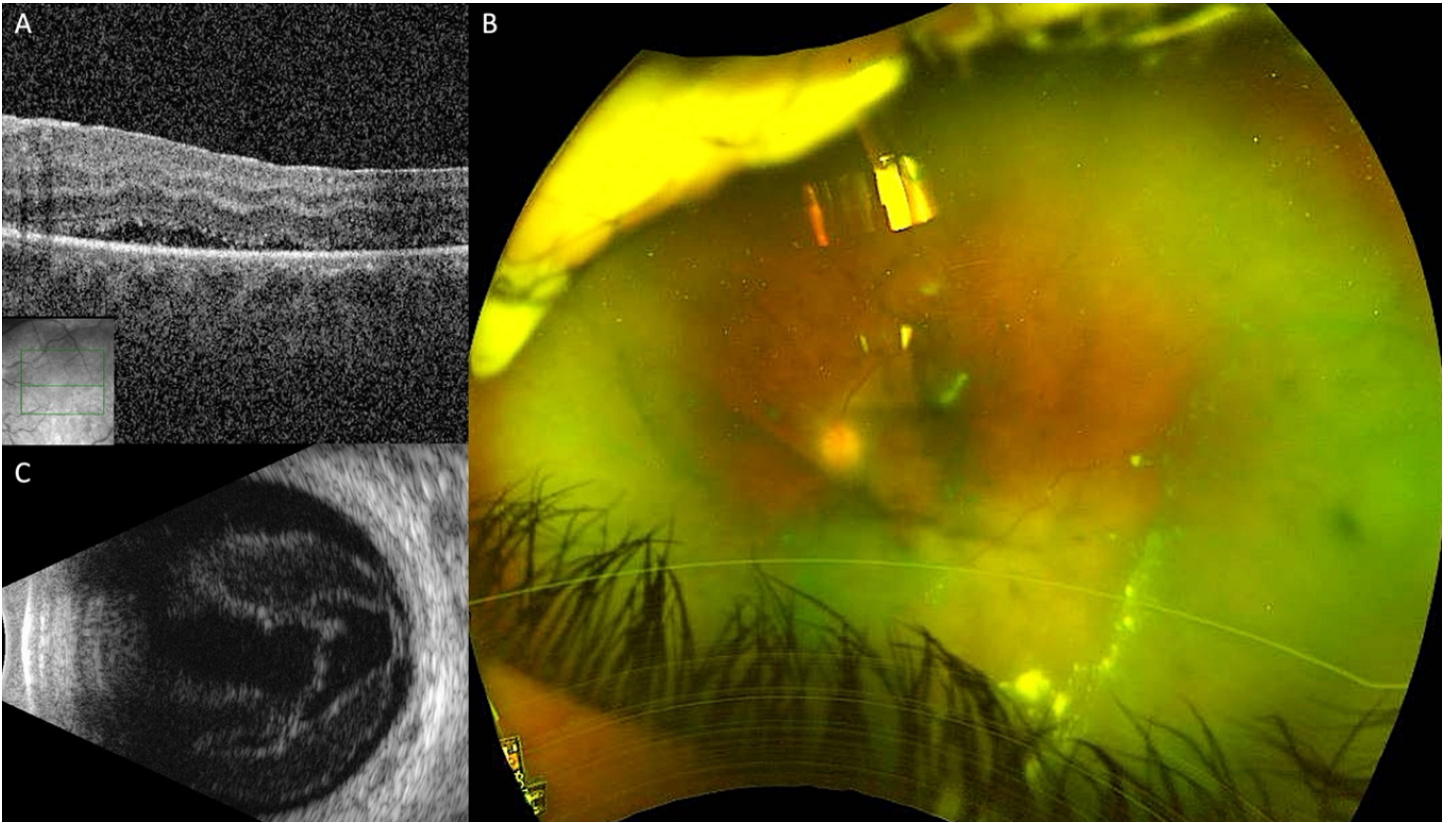
The patient underwent urgent pars plana vitrectomy with intravitreal vancomycin, ceftazidime, and voriconazole. Intraoperatively, fluffy round opacities in the vitreous were seen, thought to be most consistent with fungal endophthalmitis. Postoperatively, the patient reported subjective improvement in symptoms, and visual acuity improved to counting fingers. Intravenous antibiotics, including vancomycin and cefepime, and the oral antifungal fluconazole were continued.

Gram stain of the undiluted vitreous sample showed abundant polymorphonuclear cells but no organisms. Vitreous cultures grew gram positive cocci *G. adiacens*. Fungal cultures were negative. A transthoracic echocardiogram showed no signs of endocarditis, and blood cultures remained negative.

One week postoperatively, the visual acuity improved to 20/400. Optical coherence tomography (OCT) revealed that the macula was attached with retinal thickening, trace subretinal fluid, and early epiretinal membrane formation (Figure 1A). In the remaining vitreous skirt, residual vitreous opacities were present inferiorly (Figure 1B). Repeat B-scan ultrasonography demonstrated an attached retina with no serous choroidal detachment (Figure 1C). At postoperative month 1, examination showed significant clearing of the vitreous opacities.

Oral fluconazole was continued, in addition to the intravenous cephalosporin, during his hospitalization given the clinical concern for fungal endophthalmitis, despite no fungal elements on gram stain and the negative fungal cultures. During the hospital stay, intravenous ceftriaxone was specifically selected to replace cefepime by the infectious disease team based on potential of *G. adiacens* to cause endocarditis, despite documented susceptibility of this organism to oral agents.

The patient was discharged home on parenteral ceftriaxone and oral fluconazole. After completing approximately 5.5 weeks of outpatient treatment with these antimicrobials, the patient significantly improved, at which time treatment was discontinued. Visual acuity improved to 20/125 in the left eye, the eye was quiet, and the retina remained attached. The patient was subsequently lost to follow-up.



**Figure 1.** Findings one week after vitreous surgery. A. Optical coherence tomography (OCT) of the left eye demonstrated retinal thickening and thin subretinal fluid. An epiretinal membrane was also present. B. Ultra-widefield fundus photography of the left eye reveals residual vitreous opacities inferiorly and in the periphery. C. B-scan of the left eye post-vitreotomy is notable for prominent vitreous opacities.

## Discussion

We report a case of endogenous endophthalmitis, initially suspected to be a fungal endophthalmitis, in a patient with previous history of IVDU that was caused by *G. adiacens*, a type of nutritionally variant Streptococcus. This organism has not been previously described as a cause of endogenous endophthalmitis.

In this case, the clinical and intraoperative findings of dense vitreous opacities consistent with fungal balls led to the initial suspicion of fungal endogenous endophthalmitis which proved to be incorrect. Since over half of all endogenous endophthalmitis cases are associated with fungal pathogens such as *Candida* species,<sup>3</sup> a fungal etiology was high on the differential diagnosis. Typical presentations of fungal endophthalmitis were also similar to this case and included a gradual, subacute onset, typically worsening over days to weeks. This slower course contributes to the commonly delayed diagnosis of a fungal etiology.<sup>3,4</sup> Endogenous *Candida* endophthalmitis is classically identified by the progression of a chorioretinitis expanding into the vitreous gel, resulting in the formation of distinctive “puff ball” lesions in the vitreous,<sup>5</sup> similar to the fungal balls noted in this case.

Gram-positive bacteria such as *Streptococcus* and *Staphylococcus*, however, are also known to cause endogenous endophthalmitis, particularly in the setting of IVDU, with *Bacillus* species being notably prevalent.<sup>1,6</sup> In fact, bacterial endophthalmitis typically develops more rapidly than fungal endophthalmitis even though it shares some initial signs and symptoms with its fungal counterpart, including blurred or decreased vision, conjunctival hyperemia, intraocular inflammation, and eye pain.<sup>4</sup> Bacterial endophthalmitis also shares certain risk factors, including diabetes, malignancy, gastrointestinal surgery, and IVDU, with fungal endophthalmitis.<sup>1,4,5,7,8</sup> The patient’s IVDU was a major risk factor, as he was otherwise healthy. Growth of *G. adiacens* from the vitreous sample, a previously unreported bacterial pathogen in cases of endophthalmitis, contributes to the understanding of the range of pathogens that may cause endogenous endophthalmitis.

*G. adiacens*, a gram-positive cocci, is part of the normal flora of the oral cavity, pharynx, urogenital, and intestinal tract.<sup>2</sup> The precise *G. adiacens* species were initially identified as gram-positive bacteria with specific nutritional requirements and were thus referred to as nutritionally variant Streptococcus species, though the various taxonomic classifications have evolved over the years.<sup>9</sup> This bacterium can cause rare but serious infections, such as infective endocarditis, which may be under-recognized due to its fastidious nature and difficulties in diagnosis,<sup>9</sup> but it has not yet been described in a case of endogenous endophthalmitis. There was no evidence of valvular vegetation on the transesophageal echocardiogram of this patient, and the precise source of bloodstream entry of this pathogen in our case is unknown but may have been during IVDU.

Identifying *G. adiacens* species in blood cultures can be challenging due to its pleomorphic nature and slow growth. Various diagnostic methods, including molecular techniques such as polymerase chain reaction amplification of the ribosomal RNA and mass spectrometry, may be used for accurate and rapid identification.<sup>9</sup> Treatment guidelines for infective endocarditis caused by these organisms involve relatively long-term antibiotic therapy, often including penicillin or vancomycin in combination with gentamicin. Treatment failures are common, and the duration of therapy is determined on a case-by-case basis. There are challenges posed by antibiotic resistance, particularly to penicillin, and thus susceptibility testing is vital in guiding treatment decisions. In our case, this patient’s organism was found to be susceptible to several oral agents, but he was initially continued on both intravenous ceftriaxone and oral fluconazole for complete coverage of possible bacterial and fungal pathogens as well as concern for potential endocarditis.

This patient did achieve some visual improvement following prompt surgical and antimicrobial interventions. Timely diagnosis and treatment are key to managing endogenous endophthalmitis successfully; yet, even with these measures, many patients still suffer poor visual outcomes.<sup>1</sup> This patient was ultimately lost to follow-up, which is not uncommon among patients with endogenous endophthalmitis as they often have numerous comorbidities such as HIV/AIDS or diabetes in addition to IVDU.<sup>10</sup>

## Conclusion

We describe *G. adiacens* species causing endogenous endophthalmitis in a patient with a history of IVDU. This atypical case highlights the importance for clinicians to consider a diverse range of pathogens when diagnosing and treating endogenous endophthalmitis.

## References

1. Cunningham ET, Flynn HW, Relhan N, et al. Endogenous Endophthalmitis. *Ocul Immunol Inflamm.* 2018;26(4):491-495.
2. Chesdachai S, Yetmar ZA, Tabaja H, et al. Contemporary Experience of Abiotrophia, Granulicatella and Gemella bacteremia. *J Infect.* 2022;84(4):511-517.
3. Schiedler V, Scott IU, Flynn HW, et al. Culture-Proven Endogenous Endophthalmitis: Clinical Features and Visual Acuity Outcomes. *Am J Ophthalmol.* 2004;137(4):725-731.
4. Durand ML. Bacterial and Fungal Endophthalmitis. *Clin Microbiol Rev* 2017;30(3):597-613.
5. Abu Talib DN, Yong MH, Nasaruddin RA, et al. Chronic Endogenous Fungal Endophthalmitis: Diagnostic and Treatment Challenges: A Case Report. *Medicine (Baltimore).* 2021;100(14):e25459.
6. Benusic MA, Press NM, Hoang LM, et al. A Cluster of Bacillus Cereus Bacteremia Cases Among Injection Drug Users. *Can J Infect Dis Med Microbiol J Can Mal Infect Microbiol Medicale.* 2015;26(2):103-104.
7. Rao NA, Hidayat AA. Endogenous Mycotic Endophthalmitis: Variations in Clinical and Histopathologic Changes in Candidiasis Compared with Aspergillosis. *Am J Ophthalmol.* 2001;132(2):244-251.
8. Jackson TL, Paraskevopoulos T, Georgalas I. Systematic Review of 342 Cases of Endogenous Bacterial Endophthalmitis. *Surv Ophthalmol.* 2014;59(6):627-635.
9. Christensen JJ, Facklam RR. Granulicatella and Abiotrophia Species from Human Clinical Specimens. *J Clin Microbiol.* 2001;39(10):3520-3523.
10. Vaziri K, Pershing S, Albin TA, et al. Risk Factors Predictive of Endogenous Endophthalmitis Among Hospitalized Patients with Hematogenous Infections in the United States. *Am J Ophthalmol.* 2015;159(3):498-504.

### Statement of Ethics

This case report adheres to patient confidentiality and ethical principles in accordance with the guidelines of the Declaration of Helsinki and relevant local regulations. Consent was obtained from the patient for the publication of this case report.

### Conflict of Interest Statement

The authors declare no conflicts of interest related to this topic.

### Funding

This work received no funding or grant support.

### Authorship

We attest that all authors contributed significantly to the creation of this manuscript, each having fulfilled the criteria as established by the ICMJE.